

# Villar's Nodule: A Rare Case Report

KULADEEPA ANANDA VAIDYA, PRASHANTH ADIGA, LAKSHMAN.I.K

## ABSTRACT

Villar's Nodule or primary umbilical endometriosis is a rare condition, with an estimated incidence of 0.5 to 1% among all the patients with endometrial ectopia. Endometriosis remains a diagnostic

and therapeutic enigma even today, largely due to its variable presentations. We are hereby reporting a case of primary umbilical endometriosis due to its rarity and unusual presentation.

**Key Words:** Umbilical, Endometriosis

## INTRODUCTION

Umbilical endometriosis, also known as Villar's Nodule, was first described by Villar in 1886. It is extremely rare, the incidence being only 0.5-1% among all the women with extra gonadal or external endometriosis [1]. This condition should not be mistaken for scar endometriosis which occurs in a sub-umbilical incision scar [2]. Various theories with regards to its pathogenesis have been suggested, none of which can unequivocally account for the endometriosis in all the various locations in which it has been reported. The umbilicus is one of the less common sites for the localization of the ectopic endometrium. According to the literature, a total of only 109 cases of umbilical endometriosis has been reported [3]. The presentation of endometriosis to the general surgeons is rare and atypical and it presents diagnostic difficulties [4,5].

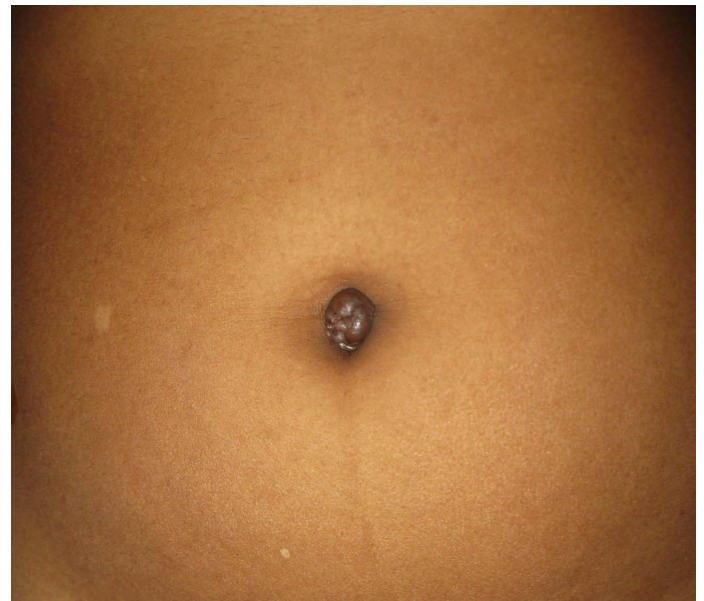
## CASE REPORT

A 30-year old woman presented with a dark brown, painless umbilical nodule of 1 year's duration and a history of cyclical bleeding from the umbilicus during menstruation [Table/Fig-1]. Surgical excision of the lesion and reconstruction were performed and the post-operative course was uneventful. Grossly, the umbilicus showed nodularity on its surface and the cut section of the resected umbilicus showed multiple, tiny cystic structures which were filled with a brownish material [Table/Fig-2]. Microscopically, the islands of the endometrial glands and the stroma were appreciated below the stratified squamous epithelium [Table/Fig-3 & 4]. A pathological diagnosis of umbilical endometriosis was given.

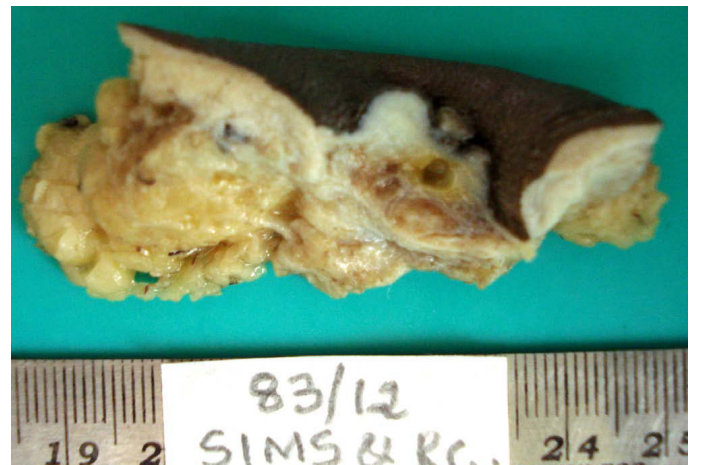## DISCUSSION

Endometriosis, which is defined as the presence of endometrial tissue (glands and stroma) outside the uterine cavity, affects 5 to 10% of the fertile women. The most pronounced symptoms are dyspareunia, pelvic pain, and infertility [6]. The other symptoms may include diarrhoea or constipation (in particular, in connection with menstruation), abdominal bloating (in connection with menstruation), heavy or irregular bleeding and fatigue [7]. The clinical presentations of umbilical endometriosis are an umbilical pigmented nodule and umbilical weeping, especially cyclical bleeding and cyclical pain [8]. Most of the endometrial deposits are

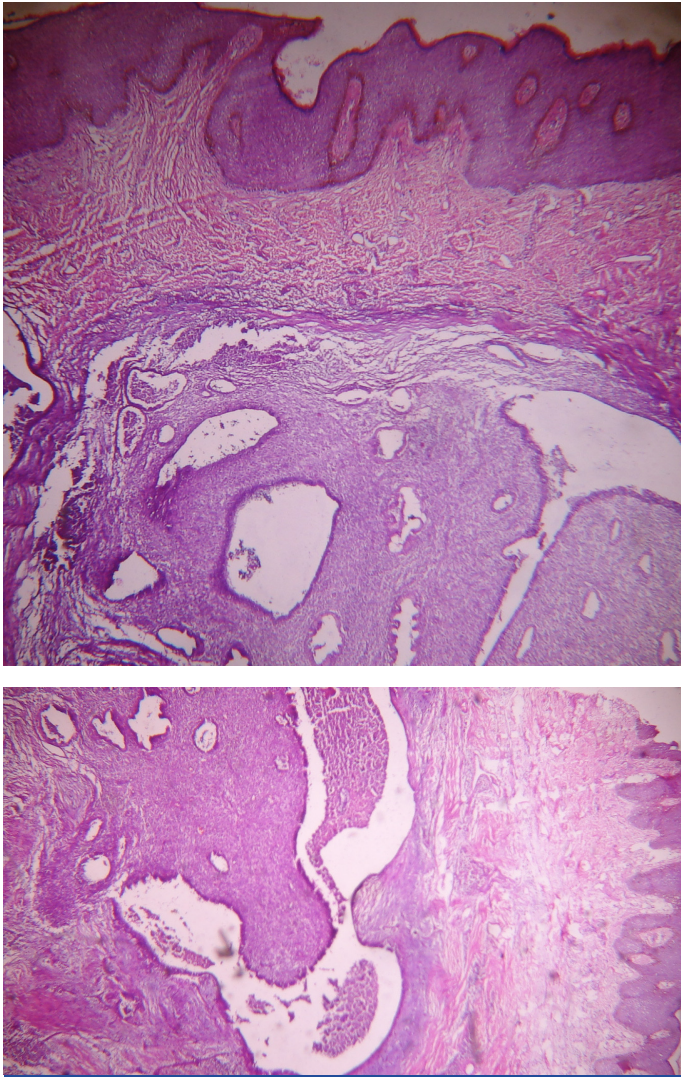
found in the pelvis, which include the ovaries, the peritoneum, the uterosacral ligaments, the pouch of Douglas, and the rectovaginal septum, but they may also rarely occur in extra pelvic locations. These include most of the body cavities, as well as organs which



**[Table/Fig-1]:** Dark brown, painless umbilical nodule



**[Table/Fig-2]:** Cut section of umbilicus: multiple tiny cystic structures filled with brownish material



**[Table/Fig-3 & 4]:** Islands of endometrial glands & stroma below the stratified squamous epithelium

include the lung, gallbladder, bowel, kidney, central nervous system, extremities, perineum, and the abdominal wall. Extra pelvic endometriosis may occur in up to 12 percent of the women with endometriosis. More commonly, cutaneous endometriosis occurs in the surgical scars from abdominal or pelvic procedures, which include hysterectomies, caesarean sections, episiotomies and laparoscopy [9,10,11].

Umbilical endometrioma is a rare condition, with an estimated incidence of 0.5 to 1% among all patients with endometrial ectopia. The development of umbilical endometriomas can occur following laparoscopic surgical procedures which involve the umbilicus [12,13]. Several aetiological theories have been proposed for its pathogenesis, with coelomic metaplasia being the most favoured one and also, the umbilicus may act as a physiological scar with a predilection for the endometrial tissue, in the development of spontaneous umbilical endometriosis [14,15]. Umbilical endometriosis can pose a diagnostic dilemma as it can simulate a malignant melanoma or the "sister Mary Joseph nodule"—a manifestation of an intra-abdominal malignancy. Any other condition that presents with a subcutaneous mass or discolouration of the umbilical skin, such as a benign nevus, a lipoma, an abscess, a cyst, or a hernia, as well as a metastatic deposit from a systemic malignancy, should be considered in the differential diagnosis [16,17]. Primary umbilical endometriosis is defined as the presence of ectopic endometrial glands within the umbilicus without a prior history of pelvic endometriosis [17].

The treatment of umbilical endometriosis consists of medical and surgical approaches. In treating pelvic pain, both drug and surgical treatments are effective [18]. Pre-operative hormone therapy may be used in patients with large mass of umbilical endometriosis, to reduce the size [19]. Umbilical defects which result from the resection of umbilical endometriosis can mostly be repaired directly by using a local advancement flap, a pedicled flap or a modified unfolded cylinder flap [20].

Some rare cases had undergone malignant transformation and they had given rise to endometrial carcinomas. The possibility of a coexisting genital-pelvic endometriosis should be investigated. Hormonal therapy may be a consideration when there is a coexistent pelvic endometriosis [21].

## CONCLUSION

Primary umbilical endometriosis is a rare condition with an overall incidence of around 0.5% to 1% among all the endometriosis cases, but sometimes, it poses a diagnostic dilemma. Hence, a histopathological examination is required for the confirmation of the diagnosis. Primary umbilical endometriosis usually presents as a brown coloured umbilical nodule. The other common symptoms are, pain and bleeding. Although a preoperative hormone therapy may help in reducing the size of the umbilical lesion, surgical resection remains the treatment of choice, with an extremely low recurrence rate.

## REFERENCE

- [1] Michovitz M, Baratz M, Stavorovsky M. Endometriosis of the umbilicus. *Dermatologica* 1983; 167: 326-30.
- [2] Panicker SCR, Pillai N, Nagarsekar U. Villar's Nodule: A rare presentation of external endometriosis. *MJAFI* 2010; 66 : 70-71.
- [3] Blumenthal N.J.A. Umbilical endometriosis; a case report, *SA Medical Journal* 1981; 198-9.
- [4] Firilas A, Soi A, Max M. Abdominal incision endometriomas. *Am Surg* 1994; 60: 259-61.
- [5] Koger KE, Shatney CH, Hodge K, McClenathan JH. Surgical scar endometrioma. *Surg Gynaecol Obstet* 1993; 177:243-46.
- [6] Chatzikokkinou P, Thorfinn J, Angelidis IK, Papa G, Trevisan G. *Acta Dermatoven APA*; 2009; Vol 18 (3).
- [7] D'Hooghe TM, Hill JA. Endometriosis. In: Berek JS, Adashi EY, Hillard PA, editors. *Novak's Gynaecology*. 13th ed. Lippincott Williams and Wilkins. 2002; 887-914.
- [8] Frischknecht F, Raio L, Fleischmann A, Dreher E, Luscher KP, Mueller MD. Umbilical endometriosis. *Surg Endosc* 2004; 18: 347.
- [9] Steck WD, Helwig EB. Cutaneous endometriosis. *JAMA* 1965; 191: 167-70.
- [10] Albrecht LE, Tron V, Rivers JK. Cutaneous endometriosis. *Int J Dermatol* 1995; 34(4): 261-62.
- [11] Geranpaye L, Fadaei-Araghi M, Irani S, Shakiba B. Spontaneous endometriosis of the abdominal wall. *Acta Medica Iranica* 2009; 47(2): 154-56.
- [12] Goldberg JM, Bedaiwy MA. Recurrent umbilical endometriosis after the laparoscopic treatment of minimal pelvic endometriosis: a case report; *J Reprod Med*. 2007;52:551-52.
- [13] Michowitz M, Baratz M, Stavorovsky M. Endometriosis of the umbilicus. *Dermatologica*. 1983;167:326-30.
- [14] Agarwal A, Fong YF. Cutaneous endometriosis. *Singapore Med J*. 2008;49(9):704-09.
- [15] Yu CY, Perez-Reyes M, Brown JJ, Borrello JA. MR appearance of umbilical endometriosis. *J Comput Assist Tomogr*. 1994;18:269-71.
- [16] Skidmore RA, Woosley JT, Katz VL. Decidualized umbilical endometriosis. *Int J Gynaecol Obstet* 1996; 52: 269-73.
- [17] Yu Hsueh Y, Shieh S, Hsueh Y-Y, Shieh S-J. Primary umbilical endometriosis. *J.P.S.A.R.O.C.* 2009; 18(1) :66-69.
- [18] Olive DL, Pritts EA. Treatment of endometriosis. *N Engl J Med* 2001; 345:266-75.
- [19] Purvis RS, Tying SK. Cutaneous and subcutaneous endometriosis. Surgical and hormonal therapy. *The Journal of Dermatologic Surgery and Oncology* 1994;20:693-95.

[20] Franco D, Medeiros J, Farias C, Franco T. Umbilical reconstruction for patients with a midline scar. *Aesthetic Plast Surg* 2006;30:595-98.

[21] Shrestha NS, Pande S, Joshi M, Padhye SM. Primary umbilical endometriosis. A case report. *NJOG* 2011 May-June; 6 (1): 51-52.

**AUTHOR(S):**

1. Dr. Kuladeepa Ananda Vaidya
2. Dr. Prashanth Adiga
3. Dr. Lakshman I.K.

**PARTICULARS OF CONTRIBUTORS:**

1. Assistant Professor In Pathology, SIMS & RC.
2. Assistant Professor In General Surgery, SIMS & RC.
3. Assistant Professor In General Surgery, SIMS & RC.

**NAME, ADDRESS, E-MAIL ID OF THE CORRESPONDING AUTHOR:**

Dr. Kuladeepa Ananda Vaidya  
Department of Pathology, SIMS&RC, Srinivas Nagar, Mukka,  
Surathkal, Karnataka - 575021 (India).  
E-mail: vaidyakuldeep@gmail.com

**FINANCIAL OR OTHER COMPETING INTERESTS:**

None.

Date of Submission: **Mar 23, 2012**

Date of Peer Review: **Apr 14, 2012**

Date of Acceptance: **Apr 18, 2012**

Date of Publishing: **Jun 22, 2012**